

A practical summary for the management of wound infections and biofilms

Reviewed by:

Dr David Keast, Past Chair International Wound Infection Institute (IWII),
Wound Care Research Leader, Parkwood Institute, London, Canada

Terry Swanson, Vice Chair and Past Chair IWII, Nurse Practitioner,
Wound Management, Warrnambool, Australia

Both reviewing authors are paid consultants of Coloplast and have been compensated for their work on this project.

Introduction

This document aims to offer a simplified yet practical summary for the management of wound infections and biofilms, based on a review of published consensus, guidance, and best practice statements.

Effective wound management relies on determining the cause and identifying any related, underlying conditions that may contribute to the wound and its delayed healing (e.g. diabetes and associated comorbidities). Wound infection is a common complication leading to delayed wound healing, resulting in a cycle of pain, anxiety, and reduced quality of life for the patient as well as increased treatment costs. Implementation of effective strategies to prevent, diagnose and manage wound infection is important in reducing the burden of chronic wounds as well as mortality and morbidity rates.¹

Wound infection

Wound infection refers to the presence of microorganisms within the wound, causing local tissue damage and delayed wound healing.¹

All wounds are contaminated with microorganisms, and the host immune response is activated to eliminate these microorganisms. Success depends on a balance between the strength of the immune system and the number and virulence of the pathogens. Wound infection occurs when the bioburden becomes too much for the immune system to manage.¹

Figure 1 presents the wound infection continuum¹, with each new stage seeing higher numbers of microorganisms. The arrow depicts when biofilms can be suspected. The continuum includes recommended interventions, with topical antimicrobials indicated for local infections, and antibiotics reserved for spreading or systemic infections.¹

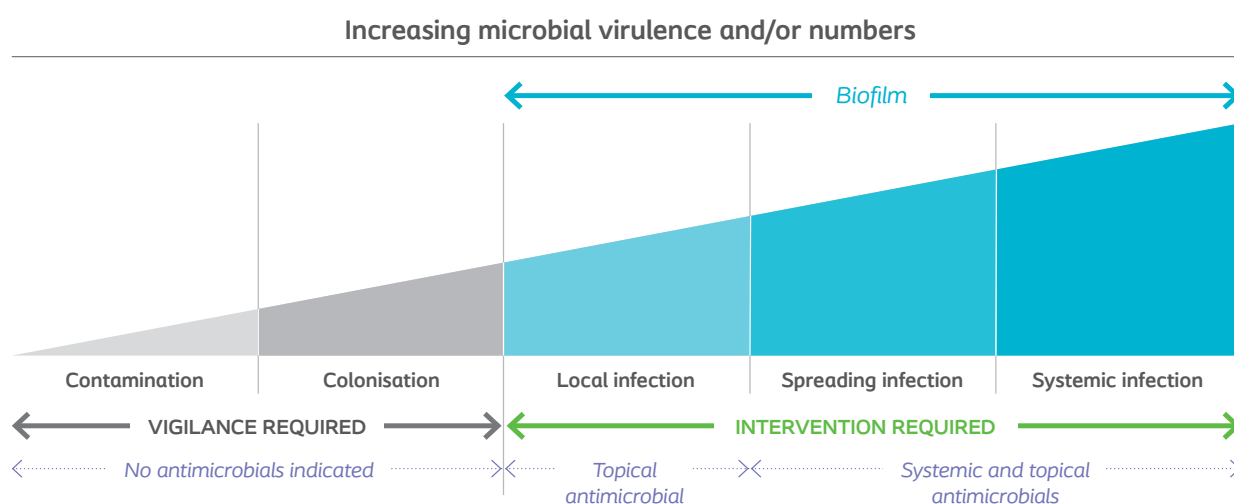


Figure 1: Wound infection continuum, reproduced from the International Wound Infection Institute (IWII)¹

Signs and symptoms of infection

The signs and symptoms of infection in Figure 2 could be used as part of a wound assessment to determine if an infection is present.² When there are signs of local wound infection, topical antimicrobials can be used, while systemic antimicrobials are needed if the infection is spreading beyond the wound area. A systemic infection needs immediate attention by a physician or wound specialist.

Signs of local infection:

- Increased pain
- Erythema
- Edema
- Local warmth
- Increased exudate
- Delayed healing
- Friable granulation
- Wound odor
- Pocketing

Signs of systemic infection:

- Increased erythema
- Pyrexia (fever)
- Abscess/pus
- Wound breakdown
- Cellulitis
- General malaise
- Raised WBC count
- Lymphangitis

Figure 2: Signs and symptoms of infection²

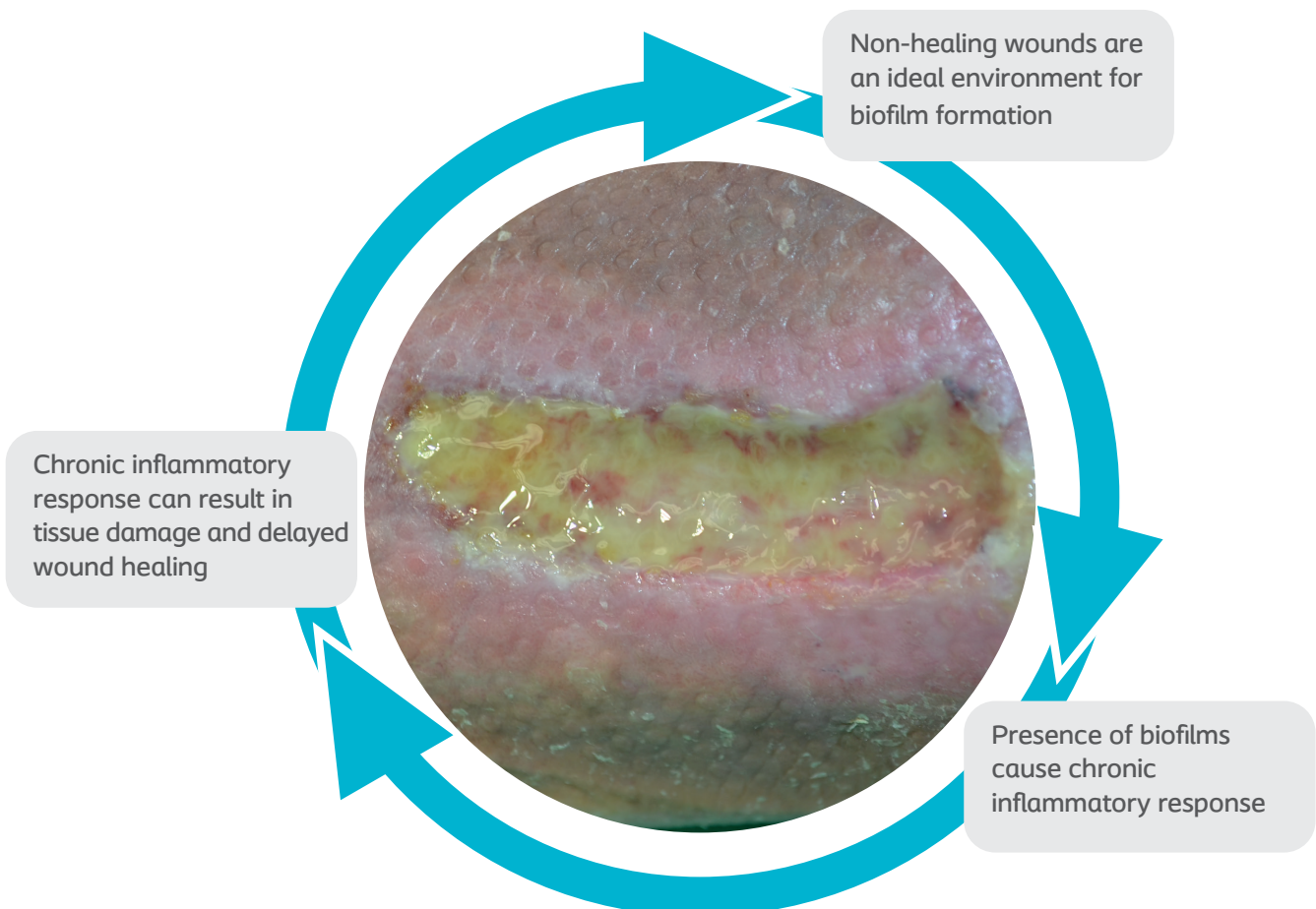
Biofilms

For a wound that is not healing in a timely fashion, despite holistic investigation and optimal intervention, biofilms are probably the most important single cause of persistent, delayed healing.³

Bacteria are often viewed as being single cells that multiply rapidly when in exponential growth. This is referred to as planktonic form and relates mostly to acute infections. However, bacteria can also form aggregates, or communities, of slow-growing cells in a biofilm form.⁴ There is increasing evidence that biofilms are present in most, if not all, chronic, non-healing wounds.³ For infections in chronic wounds it is therefore recommended to follow the guidelines for the prevention and management of biofilms.

Biofilms, or bacterial aggregates, can form within 24 hours.³ They are surrounded by a protective matrix and are difficult for the immune system and antibiotics to eradicate.⁴ Biofilms in wounds may lead to persistent infection, inflammation and delayed healing.³ Biofilms are also thought to delay wound healing by eliciting an inappropriate inflammatory response, which is ineffective and poorly orchestrated, and damaging to host tissues.³

Biofilms can keep the wound in an inflammatory state^{4,5}



Detection

Biofilms are microscopic structures, not visible to the naked eye, and detecting them requires high-powered microscopes. In a clinical setting, a tissue biopsy is the best method, but due to the small size and unequal distribution of biofilms in the wound bed, they are easily missed. Also, these techniques are both time consuming and expensive, so diagnosis of biofilms currently relies on the common signs of wound infection.³ Biofilms should be suspected in 'healable' wounds, that are non-healing, despite appropriate measures taken.²

Image 1 to the right shows a microscopic image of biofilms (highlighted red), with clusters often less than 1/10 mm – resulting in many swabs coming back inconclusive.⁶ Different species of biofilms may be present in the wound, but they are typically scattered around in small, sovereign, single-species islands. The most common biofilm formers are *Staphylococcus aureus* and *Pseudomonas aeruginosa*.

If the following signs are present despite optimal wound management and health support, they may indicate presence of biofilm¹:

- Sloughy tissue
- Increased levels of exudate
- Poor granulation/friable hypergranulation
- Malodor
- Delayed healing

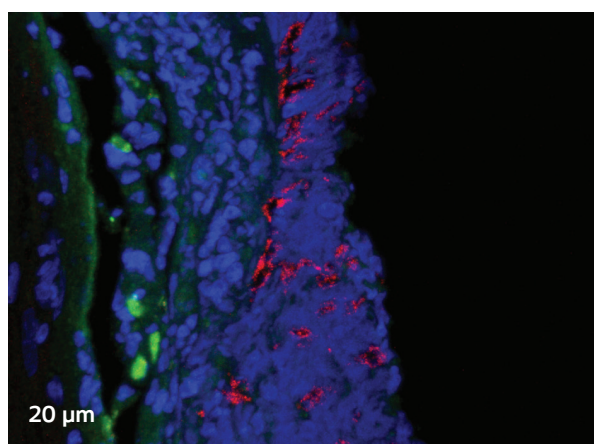


Image 1: Confocal laser scanning microscopy (CLSM)

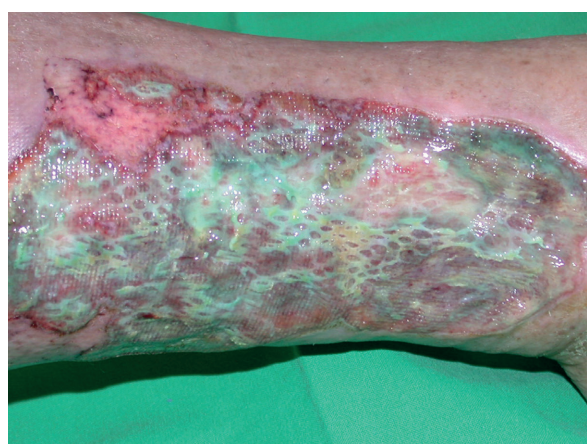

Image 2: Example of a wound with suspected biofilm

Prevention and management of biofilms

As biofilms are present in most chronic wounds, and presence of biofilms has been acknowledged as a leading cause of delayed wound healing, prevention and management of biofilms forms an important part of wound management.⁴

Prevention

New developments in wound care highlight the importance of preventing exudate pooling. Pools of exudate promote bacterial growth, leading to increased risk of infection and subsequent development of biofilm.^{2,7}

Exudate pooling is likely in wounds with irregular topographies, pockets, or cavities. It can be difficult for a non-conforming dressing to ensure close contact to the wound bed. This results in a gap between the wound bed and the dressing, where exudate can pool, increasing the risk of leakage and maceration as well as infection and biofilm formation.^{2,7,8}

An optimal wound dressing should conform to the wound bed to manage the gap and reduce exudate pooling, creating a less favorable environment for biofilm to form. Preventing biofilm formation by reducing exudate pooling can support optimal healing conditions in a wound.^{2,8}

When to manage

The actual identification of biofilms requires sophisticated lab techniques which are not available in a clinical setting.

To assess when to treat a wound for biofilms, it may help to ask these questions:

- Have all appropriate diagnostic and therapeutic measures been followed?
- Is the wound failing to heal as expected?
- Does the wound show signs of local infection or inflammation?

If the answer is Yes to at least 2 of these questions, it would be clinically relevant to treat for biofilms as summarized on the next page⁴

How to manage

Once the likelihood of biofilm presence is established, an appropriate treatment strategy should be determined. For maximum effect, assess what can be done to improve the host immune system, and always make sure to work in a clean environment.¹

Wound cleansing	Why	To remove non-viable tissue, debris, foreign matter, and excess exudate
	When	Each dressing change
	How	Irrigation with a force of 4–15 psi has been demonstrated as effective and safe ⁶
Mechanical debridement	Why	To remove and disrupt biofilms and make them more susceptible to antimicrobials ¹
	When	Each dressing change (sharp debridement as required)
	How	Physical disruption with gauze or pad by gentle circular motion in the wound bed
Manage the gap	Why	Gaps may lead to exudate pooling, bacterial growth, and development of biofilms ²
	When	Each dressing change
	How	Dressings that conform to the wound bed or wound fillers with a secondary dressing
Use topical antimicrobials	Why	Antimicrobials such as silver have been shown to kill biofilms <i>in vitro</i> ¹
	When	Directly after disruption by mechanical debridement
	How	In particular, both silver and cadexomer iodine have been shown to kill biofilms
Re-assess regularly	Why	To ensure wound progression and enable change of treatment if the wound is not healing
	When	At every dressing change or at least once per week
	How	Re-assess the questions presented above

Conclusion

In summary, the best strategy for biofilm-based wound care is the 'clean and cover' approach, which relies on adequate debridement to disrupt biofilms, and the use of antimicrobial dressings between debridements to reduce the ability of planktonic bacteria to re-establish biofilms.⁶

References

1. International Wound Infection Institute (IWII) Wound infection in clinical practice. Wounds International 2016.
2. Dowsett C et al. A focus on the Triangle of Wound Assessment – addressing the gap challenge and identifying suspected biofilm in clinical practice. Wounds International 2019;10(3):34-39.
3. Schultz G et al. Consensus guidelines for the identification and treatment of biofilms in chronic nonhealing wounds. Wound Repair and Regeneration 2017;25(5):744-57.
4. World Union of Wound Healing Societies (WUWHS), Florence Congress, Position Document. Management of Biofilm. Wounds International 2016.
5. Bjarnsholt T et al. Why chronic wounds will not heal: a novel hypothesis. Wound Repair and Regeneration 2008;16:2-10.
6. Keast D et al. Ten Top Tips. Understanding and managing wound biofilm. Wounds International 2014;5(2):20-24.
7. Dowsett C et al. Closing the gap between the evidence and clinical practice – a consensus report on exudate management. Wounds International 2020;11(3):64-68.
8. Keast D et al. Managing the gap to promote healing in chronic wounds – an international consensus. Wounds International 2020;11(3):58-63.